VERBAL AND OBJECT REASONING SHARE SOME COMMON BRAIN REGION: A FUNCTIONAL MAGNETIC RESONANCE IMAGING (fMRI) STUDY

D. Rodriguez Moreno[1], K.H.S. Kim*[1, 2] and J. Hirsch[1, 2].

Dept. of Neuroscience[1], Cornell University Weill Medical College; Dept. of Neurology[2], MSKCC; New York

INTRODUCTION

Reasoning is an essential human capacity that allows people to solve new problems. Reasoning skills have been separated into language-based and object-based reasoning and consider to be associated to different neural substrates[1]. Left hemisphere involvement is thought to be related to reasoning processes that heavily depend on language, while right hemisphere activitation is thought to be associated to visuo-spatial reasoning skills. However, imaging and lesion studies suggest that the brain regions that support these reasoning skills may not be separate. For instance, as the object reasoning becomes more abstract reasoning engages language-related areas[2]. Furthermore, evidence from split-brain patients suggest that both hemispheres are capable of non-verbal reasoning[3].

HYPOTHESIS

This study used fMRI to isolate modality-independent brain areas that are associated with sentence-based and object-based reasoning. We test the hypothesis that some of the cortical areas operating during verbal reasoning and object reasoning will be shared suggesting underlying common processes.

EXPERIMENTAL PROCEDURES

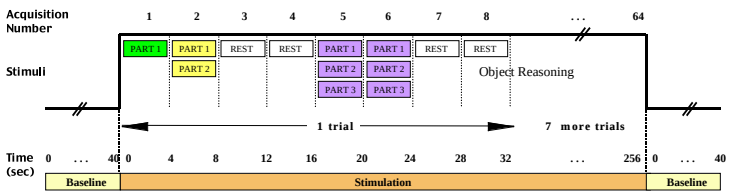

Reasoning Tasks

Reasoning	Verbal	Object
Stimulus	Visual/Auditory	Visual/Tactile
Example: PART 1	All lawyers are shy people	
PART 2	All shy people have beach houses	
PART 3	All lawyers have beach houses (True / False)	

Isolation of Decision Time after Conjunction analysis

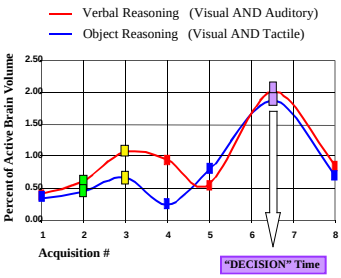

Reasoning Across Tasks: Conjunction and Exclusion

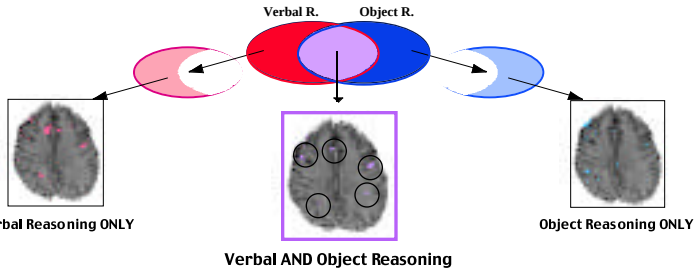

METHODS

Images were acquired on a 1.5T GE clinical scanner with echo-planar capability. T2*-weighted images were acquired using a gradient echo sequence (TR=4000msec, TE=60msec, flip angle=60deg). The in-plane resolution was 1.5 x 1.5 x 4.5 mm (128x128matrix, 19x19 cm field of view). Slice thickness was 4.5mm and 21 contiguous slices parallel to the anterior and posterior commissure line covered the entire brain. High resolution anatomical images were acquired in the same position.

5 right handed subjects performed the verbal and object reasoning tasks in visual and auditory modality or visual and tactile modality respectively. A voxel-by-voxel multistage statistical analysis was applied to isolate active voxels[4]. A conjunction analysis isolated the voxels that were associated with the verbal or the object task performed in both sensory modalities. Two logical operations, Conjunction and Exclusion, were applied to separate the brain regions associated with exclusively one or both deductive reasoning tasks[5]. A conservation approach identified the brain regions active in all subjects.

CONCLUSION

- Both verbal and figural Reasoning tasks activate specific patterns of cortical areas that involve more than language and visuo-spatial processing areas respectively.
- Many of the cortical areas operating during verbal reasoning are also active during object reasoning.
- The results suggest that verbal and object reasoning share fundamental processes that are carried out in the common areas. Then, a general pattern of brain regions may be associated with different types of reasoning skills .

RESULTS

100% Conserved Brodmann's Areas Active During Reasoning

	ANATOMICAL AREAS FOR ALL SUBJECTS	Verbal R. ONLY	Verbal AND Object Reasoning	Object R. ONLY
LEFT HEM.	Inferior Frontal Gyrus	44	44	45
	Inferior Parietal Lobule	40	40	40
	Middle Frontal Gyrus	6 , 9	6 , 9	9
	Medial Frontal Gyrus	6	6	-
	Precentral Gyrus	-	-	6
	Precuneus	-	-	19
RIGHT HEM.	Middle Frontal Gyrus	6	6	9
	Inferior Frontal Gyrus	-	-	44,45
	Inferior Parietal Lobule	40	40	40
	Precuneus	-	-	19

Coordinates of Activity for Verbal AND Object Reasoning

	100 % CONSERVED ANATOMICAL AND BRODMANN'S AREAS		TAILARAICH AND TOURNEAUX COORDINATES X	Y	Z
LEFT HEM.	Inferior Frontal Gyrus	44	45	9	23
	Inferior Parietal Lobule	40	39	-37	39
	Middle Frontal Gyrus	6	34	-1	47
	Middle Frontal Gyrus	9	43	3	36
	Medial Frontal Gyrus	6	13	2	50
RIGHT HEM.	Middle Frontal Gyrus	6	-39	10	48
	Inferior Parietal Lobule	40	-40	-39	40

SUMMARY

Brain areas Activated across Input Modalities, across Reasoning Tasks and across Individuals

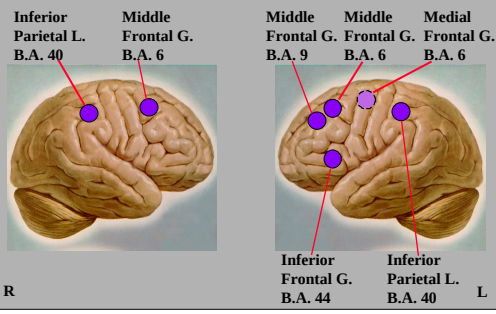

REFERENCES

1. Johnson-Laird, P.N. The Cognitive Neurosciences. Gazzaniga S., ed., Cambridge, MIT Press, 999-1008, 1994.
2. Phabhakaran, V., Smith, J.A., Desmond, J.E., Glover, G.H. and Gabrieli, J.D.E. Cogn. Psych. 33, 43-63, 1997.
3. Zaidel, E., Zaidel, D.W. and Sperry, R.W. Cortex 17, 167-186, 1981.
4. Hirsch, J et al., PNAS 92, 6469, 1995.
5. Hirsch, J., Rodriguez Moreno, D., Kim, K.H.S. Journal of Cognitive Neuroscience 13(3), 389-405, 2001.

ACKNOWLEDGEMENTS

This work was supported by the William T. Morris Foundation Fellowship (DRM and KHSK); NIH MSTP Grant (KHSK); Charles A. Dana Foundation; Johnson and Johnson Focused Giving Foundation and Cancer Center Support Grant NCI (JH). I thank the members of J. Hirsch's Laboratory for useful criticisms, the clinical MRI service at MSKCC, and all the subjects that volunteered for this study.

Address communication to D. Rodriguez Moreno / Dr. J. Hirsch at Memorial Sloan-Kettering Cancer Center, Box 506, 1275 York Av., New York, NY 10021, USA. e-mails: diana@jive.mskcc.org / hirsch@vision.mskcc.org